

Aortic stenosis and non-cardiac surgery

Jane Brown MBBS FANZCA

Nicholas J Morgan-Hughes MBChB MRCP FRCA

Goldman and colleagues identified severe aortic stenosis as a risk factor for perioperative cardiac complications in non-cardiac surgery in 1977.¹ Furthermore, they emphasized that this risk was significantly increased by the presence of coexisting cardiac failure and dysrhythmias. The National Confidential Enquiry into Perioperative Deaths has expressed concerns in several recent reports about the assessment and management of patients with aortic stenosis who undergo surgery. In the UK, aortic stenosis is most often a degenerative disease that is increasing in incidence as people live longer; it occurs frequently in patients with significant comorbidities. The condition is often unrecognized before death and post-mortem data suggest an end of life incidence of 1%. Aortic stenosis may also be present at birth; congenital malformation registry data suggest a live birth incidence of ~0.1 %.

Aetiology

Isolated aortic stenosis, without coexisting mitral valve disease, is more common in males than females and is rarely rheumatic in origin.

Degenerative calcific aortic stenosis

This is now the most common form of aortic stenosis in the UK and tends to occur over the age of 70 yr. Mechanical stress over time leads to progressive fibrosis and calcification of a previously normal tri-leaflet valve. This may be accelerated if the valve has cusps of unequal size or a degree of commissural fusion. Initially, this process is seen as 'sclerosis', i.e. areas of irregular thickening of the valve leaflets without any obstruction to left ventricular outflow. It is an early form of the disease that can progress to stenosis. Degenerative calcific aortic stenosis is associated with many of the risk factors for coronary artery disease such as diabetes, hypercholesterolaemia, smoking and hypertension. Chronic haemodialysis patients have a particularly high incidence (10%).

Congenital bicuspid aortic valve

Bicuspid aortic valve is the commonest congenital cardiac malformation (~2% of general

population). The abnormal valve structure, with two rather than three leaflets, leads to turbulent flow, which, in turn, can produce fibrosis, calcification and orifice narrowing secondary to trauma. It most commonly produces symptoms in the fourth to sixth decades of life. It accounts for 50% of patients <70 yr requiring aortic valve surgery for stenosis but only 25% of those >70 yr.

Pathophysiology

The normal aortic valve area (AVA) is 2.6–3.5 cm² in adults. Haemodynamically significant obstruction occurs as the AVA approaches 1.0 cm². The left ventricle initially responds to the increasing obstruction by hypertrophy. This allows it to maintain a pressure gradient across the valve without dilating or reducing the cardiac output. However, as the obstruction increases, detrimental consequences of hypertrophy occur. The hypertrophied ventricle becomes increasingly stiff, causing diastolic dysfunction with a reduced compliance. Consequently, left ventricular filling becomes dependent on atrial contraction with atrial systole contributing 40%, instead of the usual 20%, of left ventricular end-diastolic volume. The left atrium hypertrophies to maintain left ventricular filling. Preservation of sinus rhythm becomes vital for the maintenance of cardiac output.

Left ventricular oxygen requirements increase because of the increased muscle mass and increased left ventricular systolic pressure (and hence left ventricular wall tension). Myocardial oxygen supply is reduced owing to a relatively low aortic pressure combined with increased left ventricular diastolic pressure that reflects reduced ventricular compliance. This mismatch between oxygen supply and demand explains why patients with aortic stenosis get angina despite having normal coronary arteries. The ventricle becomes very sensitive to changes in preload, dependent on the maintenance of sinus rhythm and susceptible to ischaemia, especially when arterial pressure is reduced. Eventually, cardiac output, stroke volume and therefore pressure

Key points

Aortic stenosis increases perioperative morbidity and mortality.

Preoperative echocardiographic assessment of stenosis severity and left ventricular function is highly desirable.

Consider valve replacement before elective surgery.

Perioperative invasive monitoring is advised for patients with an aortic valve area <1.0 cm² or a mean aortic valve gradient >30 mm Hg.

Avoid hypotension and arrhythmias.

Jane Brown MBBS FANZCA

Fellow in Cardiothoracic Anaesthesia
Northern General Hospital
Herries Road
Sheffield
S5 7AU

Nicholas J Morgan-Hughes MBChB
MRCP FRCA

Consultant Anaesthetist
Northern General Hospital
Herries Road
Sheffield
S5 7AU

Tel: 0114 2714818

Fax: 0114 2269342

E-mail: n.hughes@sheffield.ac.uk
(for correspondence)

gradient across the valve fall. Left ventricular dilatation occurs late in the disease process.

The natural history of the disease is of a long asymptomatic latent period followed by the onset of characteristic symptoms. If the obstruction remains unrelieved, the average survival after the onset of angina or syncope is 2–3 yr with the development of congestive cardiac failure it is only 18 months.

Assessment

Symptoms

There are three cardinal symptoms in aortic stenosis; angina, syncope and dyspnoea. However, symptoms do not correlate well to the severity of the stenosis and some patients with small valve areas can be asymptomatic.

Angina develops as the myocardial oxygen demand outstrips supply to the hypertrophied muscle. It is present in two-thirds of patients with critical aortic stenosis, half of whom will have significant coronary artery disease. The precise pathophysiological mechanism of syncope in patients with aortic stenosis is unclear. However, the increased cardiovascular demands imposed by standing or exercise in patients with a relatively fixed cardiac output results in a drop in cerebral perfusion manifesting as a blackout or 'greying out' spell. Attacks that occur at rest may be related to self-limiting atrial or ventricular arrhythmias. Exertional dyspnoea, orthopnoea, paroxysmal nocturnal dyspnoea and pulmonary oedema tend to develop relatively late in aortic stenosis and reflect worsening pulmonary venous hypertension.

Examination

The arterial pulse in patients with aortic stenosis is typically slow rising and of low volume and, in severe cases, is associated with low systolic and pulse pressures. However, in milder cases, especially with associated aortic regurgitation or in the elderly with non-compliant vascular beds, the systolic pressure may be elevated and the pulse pressure even increased. A typical finding is a carotid thrill and, in severe cases, a lag can be detected with simultaneous palpation between the apical impulse and the carotid thrill. A precordial thrill may be felt, especially on leaning forward in expiration. Its presence is reasonably specific for severe aortic stenosis.

The murmur of aortic stenosis is a harsh late peaking systolic murmur heard best at the base of the heart at the second right intercostal space. It radiates to the carotids and to the cardiac apex, where it can be mistaken for the murmur of mitral incompetence. The physical signs change as the left ventricle fails, reducing the flow through the stenotic valve. The murmur becomes less audible, even disappearing; the slow rising pulse may be harder to detect leading to a mistaken impression of stenosis severity.

Investigations

ECG evidence of left ventricular hypertrophy is present in 85% of individuals with severe aortic stenosis. T-wave inversion and ST-segment depression become increasingly common as the hypertrophy progresses. Other ECG findings that may be present

include various forms of atrioventricular and intraventricular block attributable to extension of calcific infiltrates from the aortic valve into the interventricular septum and the cardiac conducting system.

In patients with severe aortic stenosis, the chest x-ray can be normal until left ventricular failure intervenes. Heart size is usually normal with rounding of the left ventricular border and apex. Valvular calcification is present in adults with haemodynamically significant disease and may be seen on a lateral film but is best detected with fluoroscopy. Post-stenotic dilatation of the aorta may be apparent.

Echocardiographic assessment

Echocardiography is used to assess the anatomy of the aortic valve, grade the stenosis severity and assess left ventricular function.² A clear understanding of this simple non-invasive test facilitates accurate preoperative assessment.

A 2-D examination can identify leaflet thickening, mobility and evidence of calcification. A valve with thin mobile leaflets will not have significant stenosis. Short axis views of the valve can distinguish bicuspid and tricuspid valves (Fig. 1). Continuous wave Doppler recordings are obtained from blood flow in the left ventricular outflow tract (Fig. 2). The maximum velocity, which reflects flow across the valve at peak systole, can be used to calculate the maximum pressure gradient across the valve using the modified Bernoulli equation where:

$$\text{Maximum pressure gradient (mm Hg)} = 4 \times (\text{velocity in ms}^{-1})^2$$

In practice, the sonographer uses the analysis software built into the echo machine to trace around the velocity profile of the aortic valve. As well as calculating peak gradient, the machine also calculates mean pressure gradient. It should be noted that the maximum Doppler gradient reflects the maximum pressure gradient that occurs between the left ventricle and the aorta at any point during systole (Fig. 3). This is a different value from the peak-to-peak gradient that can be measured in the cardiac catheter laboratory.

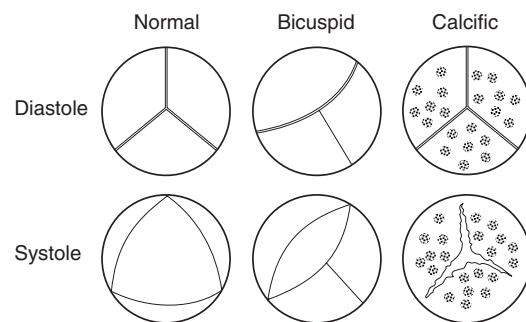


Fig. 1 Short axis 2-D echocardiographic images of the aortic valve. These demonstrate a normal valve, and the two most common pathologies that cause aortic stenosis. Note the restricted leaflet opening seen at peak systole in both the abnormal valves. In the valve with calcific stenosis the orifice displays a 'three-legged starfish' pattern that is normally associated with early systole.

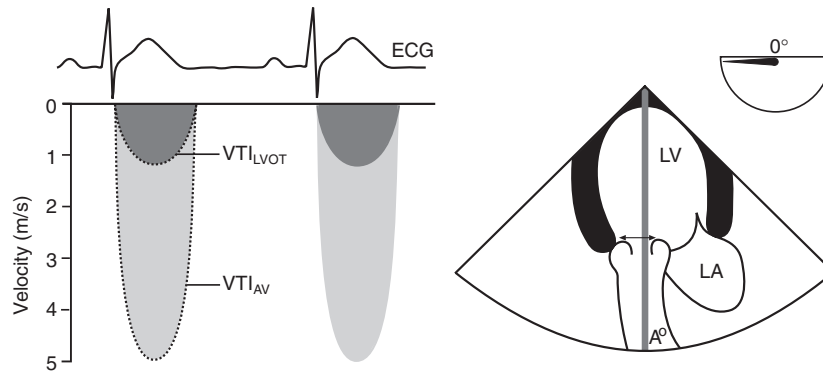


Fig. 2 To the right of the figure we see a 2-D echo image measuring the diameter of the LVOT (arrow). The cross sectional area of the outflow tract (CSA_{LVOT}) is assumed to be circular and is calculated from the diameter. LVOT is examined also using continuous wave Doppler (thick shaded line passing through open aortic valve). The resultant continuous wave Doppler trace (left of the figure) shows a 'double envelope' signal with the higher velocity lighter envelope representing flow across the stenosed aortic valve and the lower velocity darker envelope representing flow through LVOT. The peak velocity of blood through the stenosed valve is 5 m s^{-1} giving a maximum gradient of 100 mm Hg (modified Bernoulli equation). Analysis software is used to trace around both the velocity envelopes allowing calculation of the velocity time integrals for the LVOT signal (VTI_{LVOT}) and the aortic signal (VTI_{AV}) as well as maximum and mean pressure gradients for each signal. Stroke volume is given by multiplying CSA_{LVOT} and VTI_{LVOT} . Given that flow through the outflow tract is the same as flow across the valve, the AVA can be calculated: $AVA = CSA_{LVOT} \times VTI_{LVOT}/VTI_{AV}$.

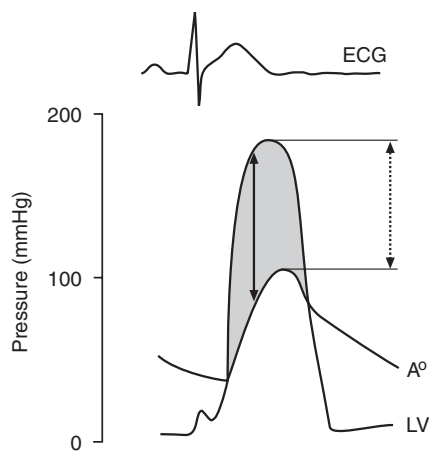


Fig. 3 Simultaneous pressure tracings from the left ventricle and the aorta in a patient with aortic stenosis. The relationship between the maximum gradient that can be measured by Doppler (solid arrow) and the peak-to-peak gradient that can be measured by cardiac catheterization (broken arrow) can be appreciated. The maximum gradient shown here is 100 mm Hg, which equates to a peak Doppler velocity of 5 m s^{-1} .

The drawback of any technique that uses the pressure gradient for grading stenosis severity is that the gradient is dependent on flow across the valve. Hence, in high output states, such as coexisting aortic regurgitation, the severity will be overestimated. Once the ventricle begins to fail because of a critical stenosis, it will be underestimated. The most accurate method of measuring the AVA using echo is with the continuity equation. This has been well validated and based on the principle that the stroke volume in the left ventricular outflow tract is equal to that through the stenotic valve orifice (see Fig. 2 for more details).

Aortic stenosis is most often classified as mild (AVA $1.2\text{--}1.8 \text{ cm}^2$, mean gradient $12\text{--}25 \text{ mm Hg}$), moderate (AVA $0.8\text{--}1.2 \text{ cm}^2$, mean gradient $25\text{--}40 \text{ mm Hg}$), severe (AVA $0.6\text{--}0.8 \text{ cm}^2$, mean gradient $40\text{--}50 \text{ mm Hg}$), or critical (AVA $<0.6 \text{ cm}^2$, mean gradient

$>50 \text{ mm Hg}$). It should be remembered that classifying by gradient, rather than area, will underestimate disease severity once the left ventricle starts to fail.

Left ventricular systolic function is classified as normal, or mildly, moderately or severely impaired based on the subjective assessment of the 2-D echo images. Left ventricular wall thickness is also measured with diastolic values $>1.0 \text{ cm}$ representing hypertrophy.

Modern echocardiography can be used to obtain all the data required before aortic valve surgery; this eliminates the need to cross the aortic valve during angiography, a manoeuvre that has significant risks. However, angiography is still indicated in patients aged $>50 \text{ yr}$ to exclude coronary artery disease, as coronary bypass grafting can be performed at the time of aortic valve replacement.

Principles of anaesthetic management

Although patients with aortic stenosis are at an increased risk of perioperative cardiac events, they can undergo non-cardiac surgery relatively safely provided that the condition is recognized and appropriate monitoring and management put in place.³ The early detection and treatment of hypotension and arrhythmias are essential.

Preoperative management

Preoperative echocardiographic assessment of stenosis severity and left ventricular function is highly desirable. It should be emphasized that even asymptomatic patients with ejection systolic murmurs may have significant aortic stenosis. Hence, where possible, even if it means delaying non-urgent surgery, patients should have an echocardiogram preoperatively. If this is not possible, patients should be managed as if they have a lesion of at least

moderate severity. In patients with a previous echocardiogram, it should be noted that aortic sclerosis is an early form of calcific stenosis that can progress and that stenosis typically worsens by a reduction in valve area of $\sim 0.1 \text{ cm}^2 \text{ yr}^{-1}$. This means that patients may warrant re-examination if the interval is $>2 \text{ yr}$ since their last echocardiogram, or less if symptoms have progressed. In addition, patients with poor left ventricular function may be incapable of producing a large pressure gradient across a stenosed valve.

Once the patient has been fully assessed, appropriate consultation with the primary surgical team, cardiologists and, if necessary, cardiac surgeons should be undertaken to determine if an aortic valve replacement is warranted before non-cardiac surgery. If the decision is that valve replacement is not appropriate, then the anaesthetist can use the echocardiographic information to form an assessment of the risk involved. This should be discussed with the patient, family and general surgical team and an informed decision as to whether to proceed can be taken.

Perioperative management

The pathophysiology of aortic stenosis determines the principles of management. Careful haemodynamic monitoring is vital. Monitoring should include an arterial catheter to detect early changes in blood pressure. Central venous access provides a route for the administration of vasoconstrictor therapy. However, pulmonary artery catheterization is relatively contraindicated because of the risk of precipitating arrhythmias. Intraoperative transoesophageal echocardiography, if available, may be appropriate and allows assessment of left ventricular filling and contractility.

Avoidance of systemic hypotension is essential. Hypotension leads to myocardial ischaemia and a downward spiral of reduced contractility causing further falls in blood pressure and coronary perfusion. Anaesthetic techniques that reduce systemic vascular resistance (e.g. regional neuroaxial techniques) must be used with extreme caution although successful cases of carefully titrated epidural and spinal blocks using catheters have been reported. Limb blocks can be useful, either alone or combined with general anaesthesia, as their effects on the sympathetic tone is more limited. For example, the use of combined paravertebral lumbar plexus and parasacral sciatic nerve blocks has been reported for use in the reduction of a fractured hip in a patient with severe aortic stenosis.

Drugs to maintain the systemic vascular tone such as norepinephrine, phenylephrine or metaraminol must be at hand. Hypotension should be treated aggressively with these drugs initially, followed by management of the underlying cause, e.g. haemorrhage. Administration of vasoconstrictors by infusion, rather than boluses, facilitates cardiovascular stability; the aim is to maintain blood pressure at normal pre-anaesthetic values.

Maintenance of sinus rhythm and adequate intravascular volume is vital to ensure ventricular filling. Arrhythmias must be treated promptly. New onset atrial fibrillation may require cardioversion, particularly if the patient is already anaesthetised. Sinus tachycardia can also be detrimental as it reduces the diastolic

time for myocardial perfusion. Plasma potassium concentrations should be monitored and maintained within the normal range. Potential surgical causes of haemodynamic instability should be considered and modified wherever possible, e.g. using a hip prosthesis that does not require cement. As for all valve lesions, appropriate antibiotic prophylaxis should be given and strict aseptic precautions adhered to.

Obstetric anaesthesia

The choice of management for pregnant patients with aortic stenosis is controversial. The estimation of stenosis severity using area rather than gradient is particularly important in pregnancy because of elevated cardiac output and flow rates. Regional anaesthesia, particularly the T4 block required for Caesarean section, carries with it a risk of significant hypotension. Traditionally, general anaesthesia was advocated for these patients and remains so in the more severe cases who are at risk of requiring emergency bypass and a combined cardiac procedure. However, it should be borne in mind that most anaesthetic agents cause vasodilatation and that it is the conduct of anaesthesia rather than the specific technique that is important. The safe use of carefully titrated regional blocks for vaginal and Caesarean deliveries using epidural and spinal catheters is increasingly reported.

Postoperative Management

Patients with aortic stenosis remain at increased risk in the postoperative period. In 2001, the Report of the National Confidential Enquiry into Perioperative Deaths recommended that patients with an aortic valve area $<1 \text{ cm}^2$, particularly in association with a reduced ejection fraction, have an indication for postoperative invasive monitoring in a high dependency setting and excellent postoperative pain control.⁴ Again, it remains vital to maintain appropriate intravascular filling and arterial blood pressure and to minimize the additional demands on the heart incurred with inadequate analgesia. Regional anaesthetic techniques have a potential role during this period but require regular review by the Acute Pain Team or others experienced in their use. Concomitant vasoconstrictor infusion may be required to offset any deleterious haemodynamic consequences of central neuroaxial blocks. Non-steroidal anti-inflammatory drugs should be avoided if possible as these patients will be at risk of postoperative renal dysfunction.

References

1. Goldman L, Caldera DL, Nussbaum SR, et al. Multifactorial index of cardiac risk in noncardiac surgical procedures. *N Engl J Med* 1977; **297**: 845–50
2. Otto CM. Valvular stenosis: diagnosis, quantitation, and clinical approach. In: Otto CM. *Textbook of Clinical Echocardiography*, 2nd Edn. Philadelphia: WB Saunders Company, 2000; 229–64
3. Torsher LC, Shub C, Rettke SR, et al. Risk of patients with severe aortic stenosis undergoing noncardiac surgery. *Am J Cardiol* 1998; **81**: 448–52
4. NCEPOD. Changing the way we operate. The 2001 Report of the National Confidential Enquiry into Perioperative Deaths. London, 2001

See multiple choice questions 1–4.