

## NERVE BLOCKS FOR ANAESTHESIA AND ANALGESIA OF THE LOWER LIMB - A PRACTICAL GUIDE: Femoral, Lumbar plexus, Sciatic

Dr Simon Morphett, Specialist Registrar in Anaesthetics, Derriford Hospital, Plymouth, UK.

### Introduction

The purpose of this guide is to provide a detailed, step by step description of how to safely and reliably perform nerve blocks for surgery and pain relief on the lower limb, for the non-specialist anaesthetic practitioner. It covers femoral nerve blockade, lumbar plexus blockade using the inguinal paravascular approach and sciatic nerve blockade. No description is given of more distal blocks, since the majority of the limb is readily anaesthetised with the techniques described and as a group they are relatively simple, reliable and commonly used.

### Conduct of nerve blocks

It is recommended that all blocks on major nerves be carried out on patients that are awake or only lightly sedated, as it is believed that this decreased the risk of serious nerve damage, and will not hide the signs of unexpected local anaesthetic toxicity. Sedated patients must still be able to communicate with the operator during the nerve block procedure. It is also recommended that a nerve stimulator be used if one is available as this increases the success rate of the blocks especially in inexperienced hands.

### Local anaesthetic drugs and dosages

For fast onset and short duration blocks, lignocaine (maximum 4mg/kg) or lignocaine with adrenaline 1:200,000 (6mg/kg) can be used. When injected into a plexus or near a large nerve such as the sciatic nerve the block will come on at about 10-20 mins and last for 4-8 hours. The adrenaline will prolong the block but may possibly increase the risk of nerve damage through ischaemia. Bupivacaine in a maximum dose of 3mg/kg will give a block of a major nerve that will start at 20-30 minutes and last as long as 18 hours. There is no value in adding adrenaline to bupivacaine except for local skin infiltration.

### Anatomy

The nerve supply of the lower limb is derived from the lumbar and sacral plexuses, a network of nerves composed of the anterior primary rami of all the lumbar and the first three sacral nerve roots (and sometimes with a contribution from the twelfth thoracic nerve root). Arising from these plexuses are the five main nerves that innervate the lower limb.

**The lumbar plexus:** This gives rise to the femoral nerve, obturator nerve and lateral cutaneous nerve of the thigh.

The femoral nerve runs in the groove between the psoas major and iliacus muscles, with a covering of these muscles' fascia. It enters the thigh passing under the inguinal ligament, where it is lateral to the femoral artery, whose pulsations are used to help locate the nerve. The femoral nerve block is performed at this point and there are two important features of the anatomy. Firstly, below the inguinal ligament, the femoral nerve divides into anterior and posterior branches, the anterior (superficial) branch supplying sensation to the skin of the anterior and medial thigh and a posterior (deep) branch that supplies the quadriceps muscles, the medial knee joint, and the skin on the medial side of the calf and foot (via the saphenous nerve). Therefore, the block should not be performed lower than just distal to the inguinal ligament, in order not to miss one of the branches. Secondly, as it enters the thigh, the femoral nerve has two fascial layers covering it, the fascia lata and the fascia iliaca. This is in contrast to the femoral artery, which is only covered by the fascia lata alone. This means that the nerve will lie in a different tissue plane than the artery and usually a little deeper. These coverings can be used in blocking the nerve. (See techniques).

The lateral cutaneous nerve of the thigh and the obturator nerve both have important sensory distributions (to the thigh and knee). This article does not cover blocks of these nerves as single entities. However, they can readily be blocked in conjunction with the femoral nerve, using the same technique, to produce a "3-in-1" block and this is described later. (see Blockade of the lumbar plexus using the inguinal paravascular approach).

**The sacral plexus:** This gives rise to the sciatic nerve and the posterior cutaneous nerve of the thigh. Although these nerves are formed separately within the plexus, they pass through the pelvis and buttock together and with the techniques described here are blocked with the same injection. Hence they are considered here as a single nerve trunk, and unless specifically stated, "sciatic nerve" will refer to both the sciatic nerve and the posterior cutaneous nerve of the thigh.

The sciatic nerve leaves the pelvis and enters the buttock through the greater sciatic foramen, and then passes slightly medial to the midpoint between the greater trochanter and the ischial tuberosity, lying just posterior to the hip joint. It can be blocked at several points along this course (see techniques). The sciatic nerve leaves the buttock, passing out from under the lower border of gluteus maximus muscle and runs distally down the thigh to the popliteal fossa.

*Areas supplied by the individual nerves:*

A pictorial illustration of the skin areas supplied is given in figure 1.

**Femoral nerve:** supplies skin over the anterior (front) of the thigh, the anterior knee, some of the medial (inner) thigh, via the saphenous nerve it also supplies the antero-medial aspect of the calf down to and including the medial malleolus. It has branches to the hip joint and knee joint and supplies much of the shaft of the femur. Sensation to the medial aspect of the big toe may come from the saphenous (femoral nerve).

**Lateral cutaneous nerve of the thigh:** supplies sensation to the skin over the lateral (outside) thigh, from the greater trochanter to the knee, and on to the anterior thigh.

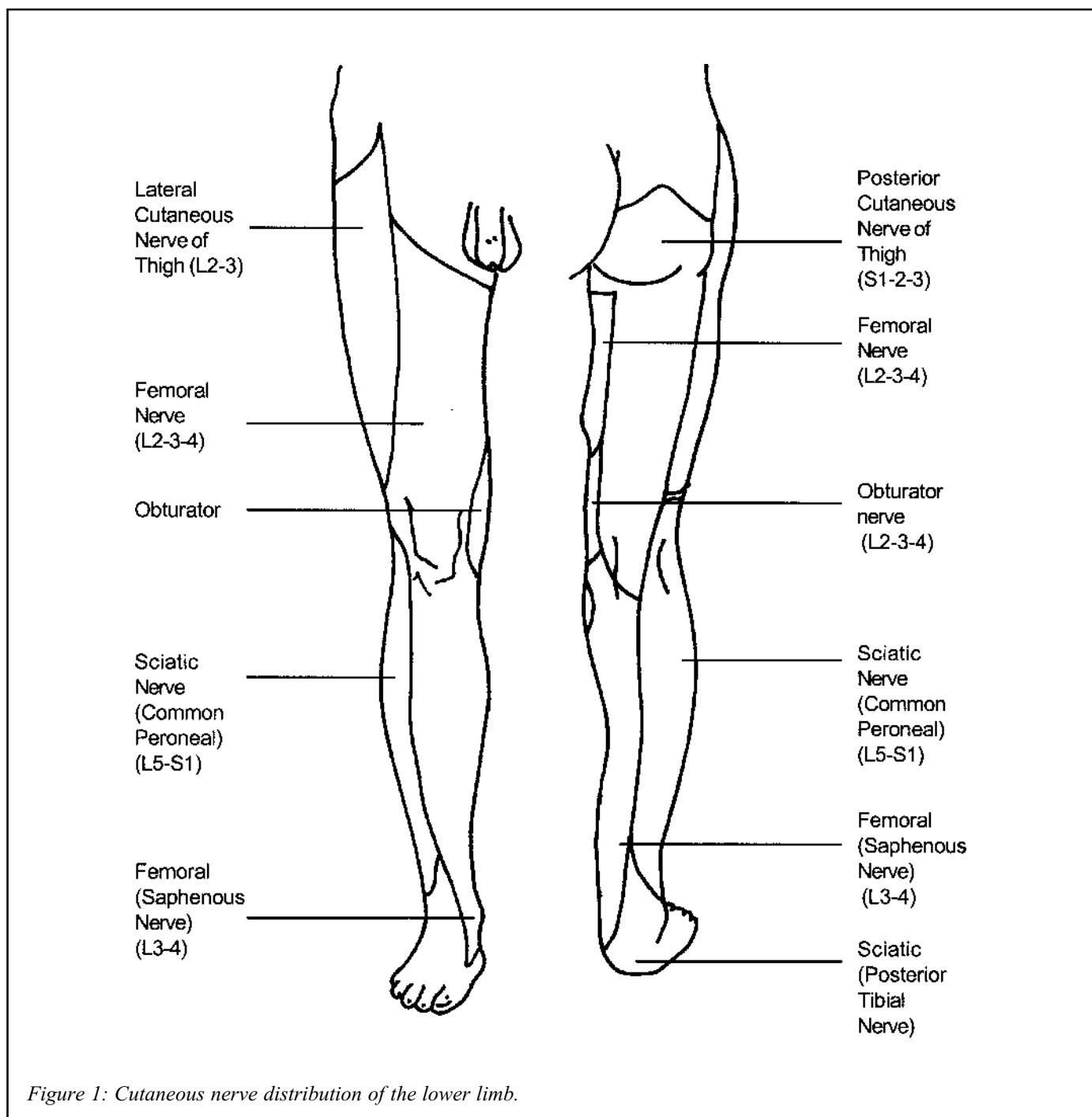


Figure 1: Cutaneous nerve distribution of the lower limb.

**Obturator nerve:** supplies a small, variable amount of skin on the medial aspect of the knee and lower thigh. More importantly, it has a branch to the knee joint. There is also a small branch to the hip joint.

**Posterior cutaneous nerve of the thigh:** supplies skin over the posterior (back) thigh, the popliteal fossa, the lower buttock and some of the genital area. Note that this nerve is blocked with the posterior approaches and is often missed with the anterior approach to the sciatic nerve.

**Sciatic nerve:** via its branches supplies all the skin of the leg below the knee and all the foot, except for the medial calf and ankle, which is supplied by the saphenous (femoral) nerve. The sciatic nerve also has a small branch to the hip joint, a branch to the knee joint and fully innervates the ankle joint.

### Surface anatomy markings

When it comes to performing the nerve blocks, it is crucial to be able to palpate and accurately locate bony landmarks, since these are the reference points we use for determining the correct site for needle insertion. The following is a description of the bony landmarks used for femoral and sciatic nerve blocks. They are shown in the diagrams of the nerve block techniques.

*Anterior superior iliac spine* following the iliac crest (ridge of the pelvic bones) from the flanks forwards, it ends in an obvious bony prominence, at the side of the lower abdomen. This is the anterior superior iliac spine.

*Pubic tubercle* is the bony prominence that can be felt at the inner (medial) end of the groin crease. It is about 2 - 4 cm from the midline, at the top of the genital area.

*Posterior superior iliac spine* is the bony prominence at the posterior end of the iliac crest. It is directly caudal to the "sacral dimple" - that depression in the skin visible cranial to (above) the buttocks, on each side, close to the midline.

*Greater trochanter* this bony landmark is part of the lateral femur, just below the hip joint. It is easy to find at the top of the thigh, protruding directly laterally. With the patient on their side, it represents the highest point on the upper thigh. In obese patients try internally and externally rotating the hip, as this makes the greater trochanter more visible.

*The sacral cornu* are two bony prominences either side of the midline just at the top end of the natal cleft. One can readily palpate a narrow depression between them - the sacral hiatus. (see figure 3)

*The ischial tuberosity* is that part of the pelvic bone structure that can be felt posteriorly, on the medial side of the base of the buttock. It is the bony structure that we "sit on."

### Indications for specific nerve blocks

From the outline of the areas covered by each nerve, the reader should know which blocks would be useful in a given situation. Two points are worth emphasising. The knee joint has significant contributions from femoral, obturator and sciatic nerves and significant injury or surgery to this joint will require that all these be blocked. (For the hip, it is nearly always sufficient to perform a 3-in-1 lumbar plexus block even though there is a small contribution from the sciatic nerve.) Secondly, the area covered by the different nerves may vary considerably and if in doubt, it is best to block both main nerve trunks.

The following are some examples of the possible uses.

#### *Femoral nerve blocks:*

- operations on the anterior thigh, such as repair of large lacerations.
- pain relief for fractures of the shaft of the femur, particularly more proximal fractures.

#### *Lumbar plexus (3-in-1) block:*

- all the uses of a femoral nerve block, plus the following:
- pain relief and anaesthesia for hip injuries such as dislocations and fractures of the neck of the femur. (Major hip surgery will also require a sciatic nerve block.)
- anaesthesia for operations on the lateral thigh such as harvesting of skin grafts, or muscle biopsies.
- pain relief for injuries and operations on the knee; extensive injuries and full knee anaesthesia require a sciatic nerve block also
- this block extends the field of a simple femoral nerve block considerably and is no more difficult to perform.

#### *Sciatic nerve block:*

- pain relief or anaesthesia for injuries or operations on the sole of the foot or any of the toes, such as toe amputation (amputation of the big toe may require supplementation at the medial malleolus as well, because the

distribution of the saphenous nerve occasionally extends down the medial side of the big toe).

- the distribution of the sciatic nerve means that it has fairly limited application as a block on its own and is most often combined with a femoral or 3-in-1 block.

#### *Combined sciatic and femoral or 3-in-1 block:*

- with this combination pain relief and anaesthesia can be provided for almost any injury or operation from the upper thigh downwards.
- one area sometimes not covered is the upper, inner thigh, and possibly the posterior thigh. This may be a problem with tourniquets applied high on the leg and in this situation some supplementary parenteral analgesia or sedation can be useful.
- it may be difficult to provide adequate anaesthesia for major hip surgery, although the blocks described will provide good postoperative analgesia.

#### *Planning the dose of local anaesthetic and dealing with possible side effects*

The above discussion will indicate that there are often situations in which one wishes to perform a combined sciatic and 3-in-1 block at the same time. This will necessitate using large volumes of local anaesthetic and the total dose administered may often be at the limit of recommended safe doses. It is important to be able to adjust the concentration of the solution injected when using large volumes, in order to keep the total dose at an acceptable level. See local anaesthetic, drugs and dosage page 56.

#### *Local complications of local anaesthetic blocks:*

The most important is damage to the nerve. Permanent nerve damage is very rare. It may be caused by accidentally injecting local anaesthetic within the nerve itself (intra-neural) or by traumatising the nerve with the needle point. Two signs of intra-neural injection are severe pain on attempted injection and marked resistance to injection. (For the patient to respond to the pain of intra-neural injection he or she must be awake, or only slightly sedated.) Either of these warning signs should prompt the operator to stop injecting and reposition the needle. Intra-neural injection may also be less likely if a short-bevel needle is used<sup>1</sup>. Paraesthesia is the “electric shock-like” feeling felt as the

nerve is touched by the needle. It should be a warning sign that nerve damage may occur if the needle is inserted further.

It is also possible to cause a haematoma by puncturing an artery with the needle - most commonly this will be the femoral artery. This is rarely of any significance. If the femoral artery is punctured then firm pressure applied to the site for 5 minutes will minimise the haematoma.

#### **Performing the nerve blocks - patient preparation and techniques**

When performing any of the blocks that are described here, the steps taken to safely prepare the patient should be carefully followed.

#### *Preparing the patient*

- **Consent** - explain the entire procedure to the patient. This will help to relieve any anxiety and increase co-operation.
- **Fasting** - if an elective procedure is planned, then the patient should be fasted similar to having a general anaesthetic. This increases safety in the event that a general anaesthetic or resuscitation is required.
- **Monitoring** - the potential complications described in the preceding section mean that monitoring is essential. If available, ECG and blood pressure monitoring should be used. If sedation is planned then a pulse oximeter should also be used. In every case, the most useful monitor is to maintain careful, continuous observation of the patient throughout. An assistant can be invaluable in helping with this.
- **Intravenous access** - because of the possible complications, should be intravenous access secured before any block is performed. This also allows administration of intravenous fluids, sedative agents and resuscitation drugs if required.
- **Positioning** - take care with positioning the patient for the block and make sure they are as comfortable as possible as this will make the block easier to perform.
- **Identify the bony landmarks** - these are described in the anatomy section.
- **Clean the site** - the skin over the block site should be cleaned with an antiseptic agent and surrounded with sterile drapes. The operator should wash their hands and wear sterile gloves.
- **Perform the block!**

- **Allow time for the local anaesthetic to take effect** - at least 15 - 20 minutes will be required for surgical anaesthesia. With the weaker concentrations of bupivacaine, 30 - 45 minutes may be required.

## Techniques

### *The femoral nerve and lumbar plexus*

**Anatomy** The femoral nerve has contributions from the second, third and fourth lumbar nerves. It is derived from the lumbar plexus and in fact lies within the same fascial envelope as the lumbar plexus. This important fact may be utilised to block most of the nerves originating in the lumbar plexus with a single injection distally, as local anaesthetic can be made to spread proximally within this plane. (See anatomy)

**Technique** (figure 2) The patient lies supine with the leg extended, lying flat on the bed. The operator stands on the side of the patient that is to be blocked. Firstly, identify the point of injection, using the surface landmarks. For the femoral nerve, this is just below (distal to) the inguinal ligament. Palpate both the anterior superior iliac spine and the pubic tubercle. The line between these two overlies the inguinal ligament. It is often helpful to draw the lines that are described on the skin. The femoral artery should lie at the midpoint of the inguinal ligament and it is necessary

to locate this by feeling for the pulse at this point. The site for injection is 1 cm lateral to (outside of) the pulsations of the femoral artery and 1 - 2 cm below (distal to) the line of the inguinal ligament. Having identified the site, it will be more comfortable for the patient if a small amount of local anaesthetic is used to create a skin wheal ("bleb") at the injection point.

An ordinary needle of length 3 - 4 cm and 21 - 23g in width is suitable for performing this block. It should be inserted perpendicular to the skin, but aiming slightly towards the head of the patient.

The following are two ways of carrying out the block. In the first technique, the operator attempts to locate the nerve by eliciting paraesthesiae, or failing this by depositing the local anaesthetic over a range of areas (the classical technique of Labat<sup>5</sup>). In the second technique, use is made of the fascial layers overlying the nerve and a single injection only is employed (Khoo and Brown<sup>2</sup>). In both cases, it is very important to remember the anatomy. The femoral nerve lies adjacent to but slightly deeper than the structures contained within the femoral sheath (the artery, vein and femoral canal). This is because the nerve lies deep to the fascia iliaca, while the contents of the femoral sheath lie on top of it.

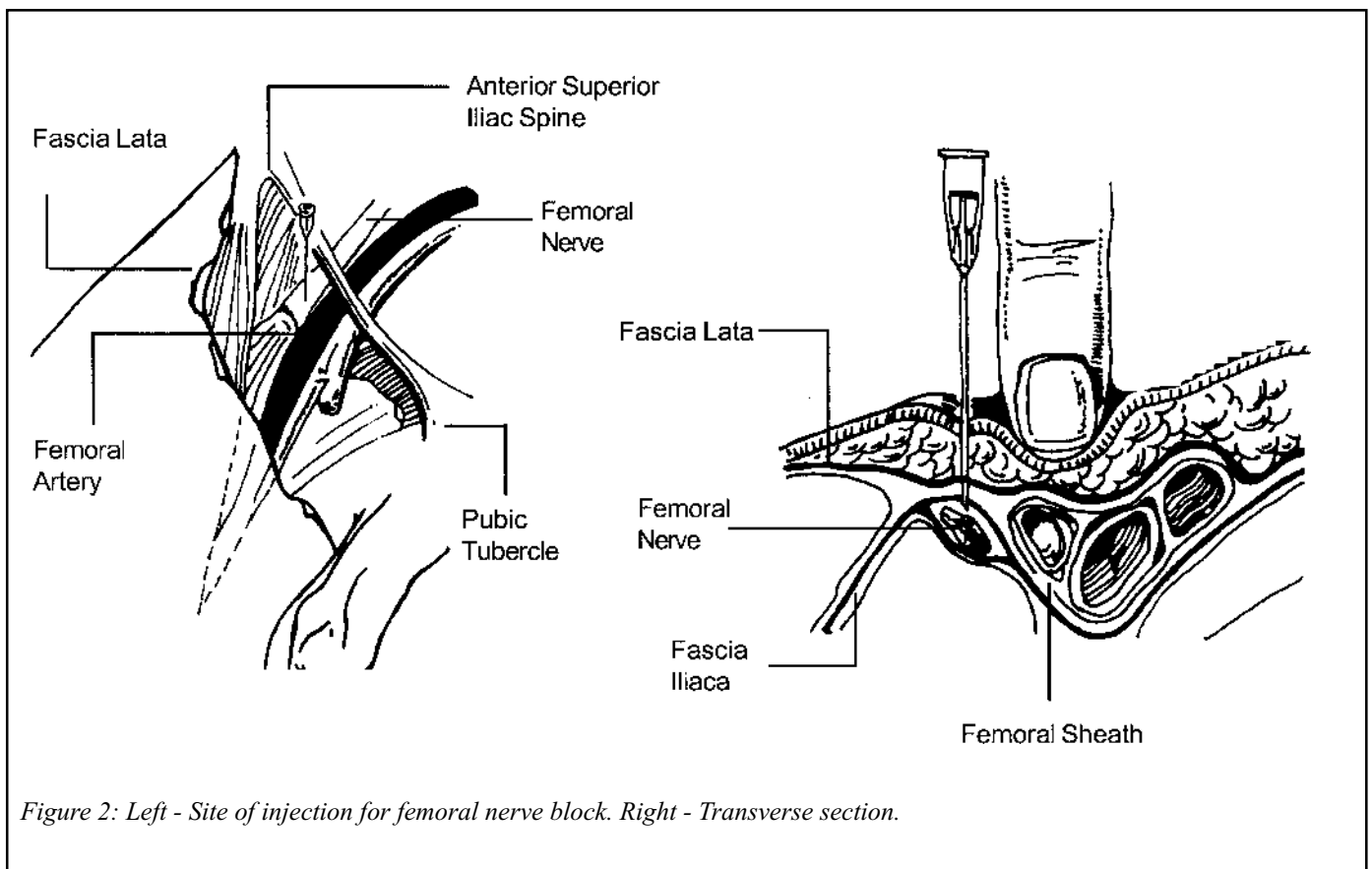


Figure 2: Left - Site of injection for femoral nerve block. Right - Transverse section.

**The classical approach** The needle is advanced through the skin, as described above, until the patient feels paraesthesiae in the distribution of the femoral nerve. If a depth of 4 - 5cm is reached and no paraesthesiae are found, then it should be withdrawn to just below the skin and advanced again in a slightly medial or lateral direction, repeating this until the patient feels paraesthesiae. Once this occurs, the needle should be fixed in position with one hand, resting this hand on the patient to try and minimise movement. With the other hand, the syringe containing local anaesthetic is then connected to the needle and gentle aspiration performed. If no blood is seen then 15 - 20 mls of local anaesthetic is injected (aspirating again regularly to check for the presence of blood).

The presence of paraesthesiae is the best indicator for correct positioning of the tip of the needle, but it is often not easy or even possible to locate the femoral nerve in this manner.

Alternatively as the needle is advanced alongside the artery, its pulsations may cause lateral (side to side) movement of the hub of the needle. If this is the case, the needle is slowly advanced and frequent observations made until the point is reached when the lateral movements are at their greatest. This generally represents a depth where the tip of the needle is just deep to the artery and should be in the correct plane. The needle is then fixed, the syringe connected and aspiration performed as before. However, only 10 ml of local anaesthetic is injected at this site. This injection is then supplemented by withdrawing the needle slightly redirecting the tip outwards (laterally), inserting to the same depth as before and injecting 3 - 4 mls of local anaesthetic (after aspiration). This process is repeated 2 or 3 times, moving progressively further laterally, such that a total of 20 - 25mls of local anaesthetic is deposited in a "fan-shaped" area lateral and deep to the femoral artery.

**The single injection technique**<sup>2</sup> This method has the virtue of simplicity and generally involves less probing with the needle. For this reason it is popular but requires some practice for a high success rate.

The site for injection is the same as already described. However, the needle is inserted directly perpendicular to the skin. If the needle is held gently between thumb and forefinger, then a slight resistance is encountered at the fascia lata, followed by a definite loss of resistance, or "pop" as the needle penetrates this layer. The same thing

is felt as the needle penetrates the fascia iliaca and comes into the proximity of the femoral nerve. Therefore, immediately on feeling this second loss of resistance, or "pop", the tip of the needle should be in the correct position. The needle is then fixed in position with one hand, the other hand again being used to connect a syringe, aspirate to check for blood and inject 20 ml of local anaesthetic.

This technique is entirely dependent on being able to detect the two points of loss of resistance as each of the fascial layers is penetrated. This is much easier if a short-bevel needle is available to use, as it does not pierce the fascia quite as easily as an ordinary needle, making the feel of the layers more obvious. If a short-bevel needle is not available, then the same effect can be achieved using an ordinary needle but blunting it prior to insertion. The "blunting" may be cleanly achieved by piercing the side of the protective plastic sheath (that comes with the needle) several times with the needle tip before performing the block. The detection of paraesthesiae is not to be recommended when using this technique as the "blunted" needle is more likely to cause nerve damage.

**Use of a nerve stimulator** If an insulated stimulating needle is available for use, then it is necessary to obtain contraction of the quadriceps muscle group. This is most reliably seen by movement of the patella and extension of the knee joint. (The movement of the knee is not normally obvious, as the patient's leg is usually flat on the bed and fully extended anyway.) The contractions should still be visible at a stimulating current of 0.3 - 0.5 mA indicating adequate proximity to the nerve. Exactly the same technique will be used if one wishes to perform a lumbar plexus block using this approach.

### **Blockade of the lumbar plexus using the inguinal paravascular approach**

This technique is also referred to as the "Winnie 3-in-1 block" after the author who first described it<sup>3</sup>. It is so called, because it aims to block three nerves with the one injection: the femoral nerve, the lateral cutaneous nerve of the thigh and the obturator nerve.

**Anatomy** For most operations on the thigh and knee it is not sufficient to block the femoral nerve alone. The lateral cutaneous nerve of the thigh supplies all the outside of the thigh and the obturator nerve supplies a variable amount of skin on the inner thigh just above the knee and contributes to the innervation of the knee joint.

All three nerves are derived from the lumbar plexus. The plexus lies on the quadratus lumborum muscle and behind

the psoas major muscle and is invested in a fascial sheath derived from these two muscles. This sheath forms a continuous covering around the plexus, extending down to the femoral nerve just below the inguinal ligament. Therefore if local anaesthetic injected around the femoral nerve at the inguinal ligament can be made to spread proximally, then the other two nerves can be simultaneously blocked at their origins from the lumbar plexus.

**Technique** The injection point and method for correct needle placement are exactly as described for the femoral nerve. It is most practical to use the single injection technique, as this will enable placement of the large volumes required.

There are two differences; the main difference comes with the actual injection of the local anaesthetic. Having aspirated on the needle to check that the tip is not intravascular, the hand is then moved to apply firm pressure on the thigh (with the thumb) about 2 - 4 cm. below the insertion point of the needle. The injection is then performed, all the while maintaining the pressure. The pressure can be released about thirty seconds after the injection has been completed. (The injection will require an assistant, as the operator will have one hand immobilising the needle and the other applying pressure.) This procedure encourages spread of the local anaesthetic upwards, towards the lumbar nerve roots.

The second difference is that larger volumes of local anaesthetic are used to achieve the necessary spread. The minimum volume to block all three nerves is 20 mls. However, many texts suggest larger volumes such as 25 - 30 mls. When using these volumes, particularly in combination with a sciatic nerve block, it may be necessary to dilute the concentration of local anaesthetic solution used in order to limit the total dose given.

Use of a nerve stimulator: as for the femoral nerve.

### The Sciatic Nerve

**Anatomy** The sciatic nerve is the largest nerve in the body, measuring about 2 centimetres in thickness in its proximal portion. In this portion it is actually made up of the sciatic nerve and the posterior cutaneous nerve of the thigh. This "double nerve" contains contributions from lumbar nerve roots 4 and 5 and sacral nerve roots 1,2 and 3. In the techniques that are described here, this large "double nerve" is considered effectively as a single nerve and blocked with the one injection. For simplicity, it is referred

to just as the sciatic nerve.

The important bony landmarks that one needs to be able to identify for blocking the sciatic nerve via the two posterior approaches described are the greater trochanter, posterior superior iliac spine, the ischial tuberosity and the sacral hiatus. For the anterior approach, the landmarks are the anterior superior iliac spine and the pubic symphysis on the pelvis and the greater trochanter on the femur.

**Technique** It will be appreciated from the description of these landmarks that there are several possible routes to block the sciatic nerve. Three of the most common approaches are described here. The first is the classical posterior approach of Labat<sup>5</sup> performed with the patient in the lateral position. The second is another posterior approach, but the patient is supine and the leg is flexed at the hip and at the knee. Finally, the anterior approach is described where the patient is supine with the legs lying naturally extended. The choice of technique will to some extent be influenced by the position that is easiest for the patient to assume. However, the success rate is higher with the posterior approaches unless a nerve stimulator is used<sup>4</sup>. Furthermore, the anterior technique tends to be technically more difficult<sup>4</sup> and therefore it is suggested that every effort should be made to position the patient for one of the posterior approaches.

**Posterior approach of Labat<sup>5</sup>** (figure 3) The patient is first placed in the lateral position with the side to be blocked uppermost. While the lower leg is kept straight, the upper leg is flexed at the knee so that the ankle is brought over the knee of the lower leg. Another way of achieving the correct degree of hip and knee flexion is to have the posterior superior iliac spine, the greater trochanter and the knee in a straight line.

*The point of injection is identified as follows:*

A line is drawn between the greater trochanter and the posterior superior iliac spine (the line lies approximately over the upper border of the piriformis muscle). From the midpoint of this line, at right angles to it, draw a second line passing down over the buttock. The point of injection is 3 - 5 centimetres along this perpendicular line. It can be more precisely identified by drawing a third line between the greater trochanter and sacral hiatus, the point of injection being where this third line intersects with the second, perpendicular line. Having identified this point, place a small wheal of local anaesthetic at the site.

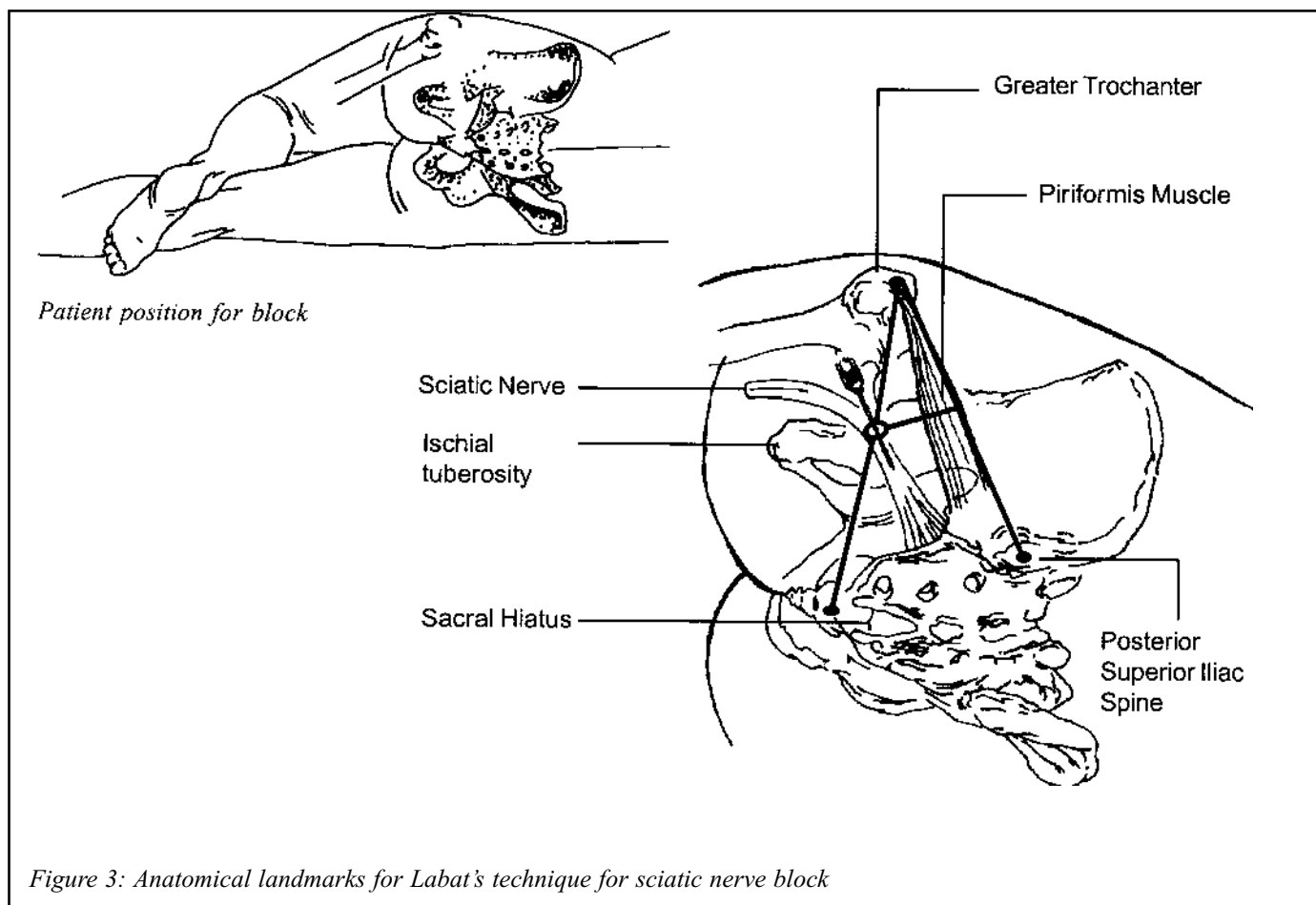


Figure 3: Anatomical landmarks for Labat's technique for sciatic nerve block

The needle that is required for this block needs to be quite long. A standard adult lumbar puncture needle is usually sufficient (9cm, 22G). In a very large person, an extra long needle, (10 - 12cm) may make the location of the nerve an easier task.

The needle is inserted perpendicular to the skin and slowly advanced until either bone is encountered, or paraesthesiae are elicited. (For the block to be successful, paraesthesiae below the knee should be felt.) If bone is encountered, the needle is withdrawn approximately 1-3cm and redirected slightly, either medially or laterally. Gentle probing within this single (transverse) plane should enable the nerve to be located by producing paraesthesiae as described. If the needle has been inserted as far as possible and neither paraesthesiae elicited nor bone encountered then the tip may have entered the greater sciatic notch. Should this occur, then the needle should be withdrawn almost fully, until the tip is just beneath the skin and then redirected in a slightly medial or lateral plane as described above.

Having located the nerve by paraesthesiae, the needle

should be fixed in position and a syringe containing approximately 20ml of local anaesthetic connected. Aspiration is performed to exclude intravascular placement of the needle and the local anaesthetic is then injected. Repeat aspiration half way through the injection, in case the tip of the needle has moved). It is important that if severe pain occurs or if there is significant resistance to injection then the operator should stop immediately and reposition the needle, as these may be signs of intraneural injection.

**Alternative posterior approach (of Raj)** If it is not possible to have the patient lying on their side, then a variation of the posterior approach may be performed with the patient supine, although the hip is still manipulated.

To perform this block, the operator stands by the patient's bed, on the side to be blocked. The hip is then flexed as much as possible with knee bent. This position can be held stable by bracing the foot against the front of the operator's shoulder as they face towards the head of the bed. Alternatively, an assistant can hold the leg steady. The greater trochanter is palpated on the outside of the leg and the ischial tuberosity is also located, being the main prominence at the base of the buttock. It is often possible



to palpate these two bony protuberances at the same time using the thumb and middle finger of the same hand. The midpoint between these two landmarks is the injection point. It is sometimes possible to identify this line joining the greater trochanter and ischial tuberosity as a depression between two muscle bellies - semitendinosus and biceps femoris.

Having located the injection point a small skin wheal is raised and the same needle as above is inserted at right angles to the skin. Once again the aim is to elicit paraesthesiae below the knee and this is achieved exactly as described above - by gentle probing in the transverse ("side to side") plane. The sciatic nerve is most likely to lie slightly medial to the path of the needle if these landmarks are used. The injection of local anaesthetic is then also performed in exactly the same manner as for the classical technique of Labat.

It should be noted that this alternative approach would block the sciatic nerve several centimetres more distally than the first approach described. However, it is rare to miss the posterior cutaneous nerve of the thigh, even with the alternative approach.

**Anterior approach to the sciatic nerve** Occasionally,

it will be not be possible to move the patient's leg from the neutral position with them lying supine. In this case a sciatic nerve block can be performed using an anterior approach although as already stated, this tends to be more of a technical challenge! This technique will also result in the sciatic nerve being blocked at a relatively distal point (just beyond the hip joint) and hence it is possible to miss the posterior cutaneous nerve of the thigh, which becomes separated from the sciatic nerve by the hamstring muscles just below the buttock.

The landmarks for the point of injection are as follows: (see figure 4) firstly, trace a line over the inguinal ligament (from the anterior superior iliac spine to the pubic tubercle) and divide it into thirds. From the junction of the inner and middle thirds draw another line at right angles to the first, going down the leg. The next step is to find the greater trochanter and from this draw another line parallel to the line over the inguinal ligament (the first line drawn). Where this last line crosses the perpendicular line (the second line) is the point of injection. A small skin wheal of local anaesthetic is then injected at this site.

The needle used for this block is a standard adult lumbar

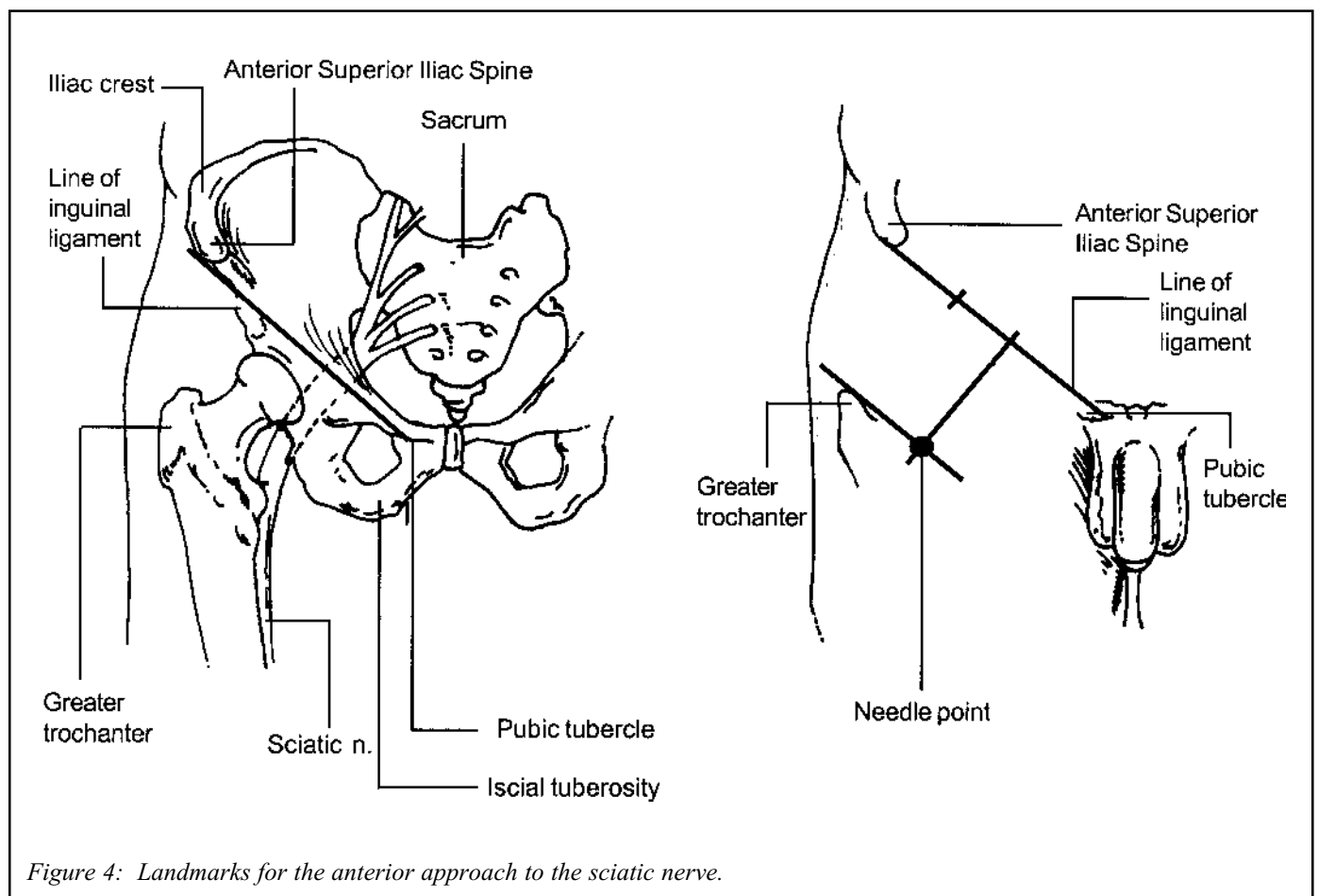


Figure 4: Landmarks for the anterior approach to the sciatic nerve.

puncture needle (9 cm long). However, the depth of insertion required for this block is commonly greater than for the posterior approaches and a longer needle is often required.

The needle is then inserted perpendicular to the skin, which means aiming in a slightly lateral direction. The operator should aim to strike bone, close to the medial edge of the femur. This will be at about the level of the lesser trochanter. The needle is then withdrawn slightly, redirected more medially (it should be more towards the vertical) and advanced, this being repeated until the needle is "walked off" the bone, the aim being to just slip past the medial edge of the femur. The operator should note the depth at which the needle initially strikes the femur. Normally this is done by carefully observing the portion of needle shaft remaining at the skin. Once the needle has been directed off the bone, as described above, it should be inserted a further 5 cm (2 inches). The tip of the needle should now be in the region of the neuromuscular bundle. (See figure 5)

Aspiration to check for intravascular needle placement is particularly important if this approach is used, as there is a higher likelihood of vascular puncture. Having aspirated, the needle is immobilised in the usual fashion and approximately 20 ml of local anaesthetic injected.

If there is resistance to injection, then the tip of the needle may still be within muscle substance. If this occurs then the needle should be slowly advanced until injection is easily accomplished.

This technique does not require that paraesthesiae are found, but if they are elicited this is a positive sign of correct needle placement.

If one wishes to be positive about the needle placement and it is not possible to elicit paraesthesiae using the anterior approach as just described, then it is sometimes helpful to use a more medial injection point (about 1 - 2cm inside of the one described). This means that the needle will pass the medial edge of the femur at more of an angle than

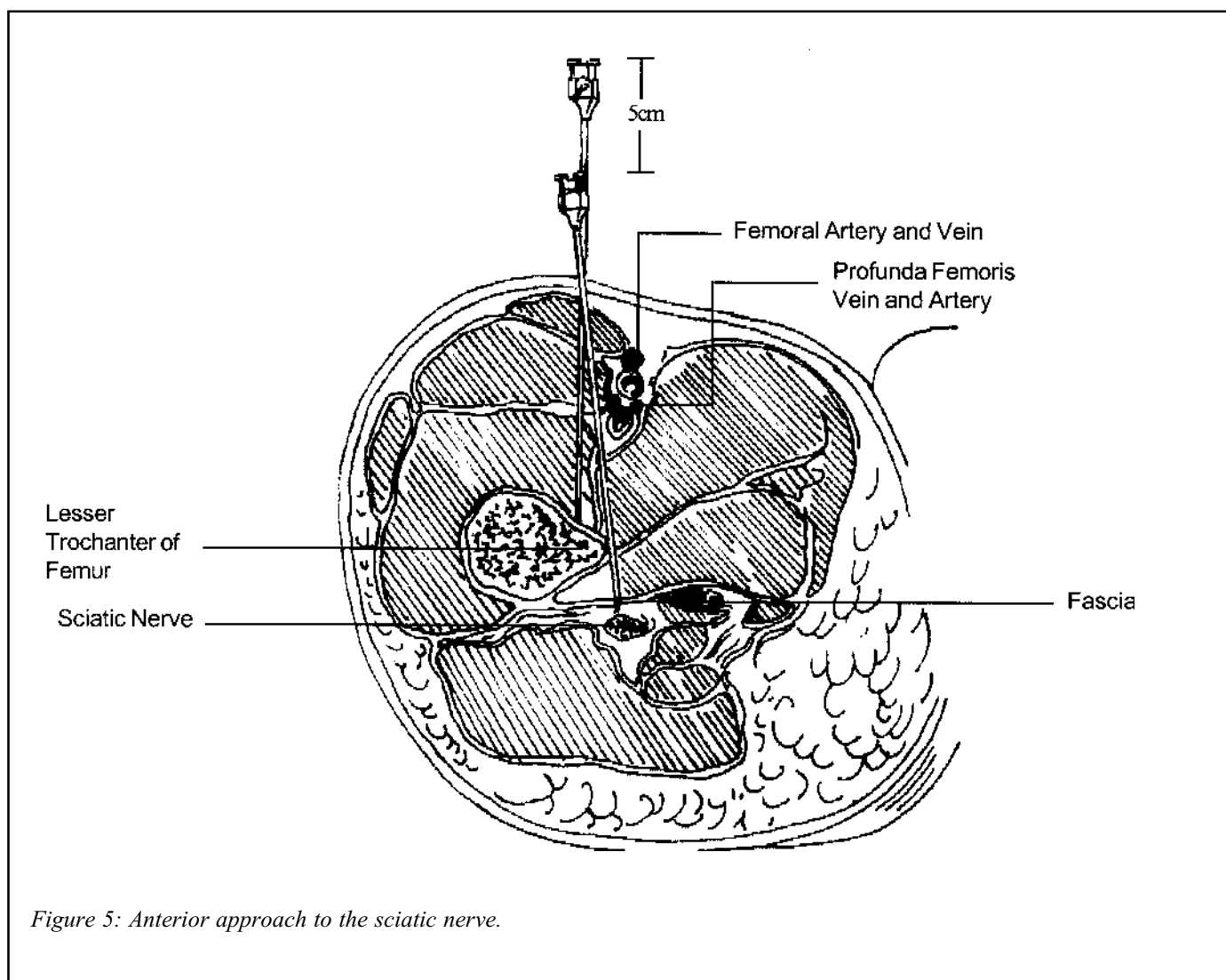


Figure 5: Anterior approach to the sciatic nerve.

before and the tip will end posterior to the femur. This may help find the nerve, which tends to lie slightly behind the femur at this level. (When using this more medial injection point, it may help to place the free hand under the buttock and palpate the ischial tuberosity. The needle is then aimed at a point estimated to be 1 - 2cm lateral to the ischial tuberosity.)

Performing a sciatic nerve block using a nerve stimulator A nerve stimulator may be used in conjunction with any of the approaches to the sciatic nerve that have been described above. The techniques for determining the point of injection and locating the nerve are no different, except that one will look for muscle contraction. The best indicator of proximity to the nerve is dorsiflexion of the foot at the ankle and one should aim to achieve this at a stimulating current of 0.3 - 0.5 mA. However, when using the posterior approaches, one may also see contraction of the "hamstring" muscles down the back of the thigh, which may be taken as a sign of proximity to the sciatic nerve.

Having achieved muscle contraction at the required stimulating current, injection of local anaesthetic is performed in the usual manner.

#### **Acknowledgements**

I would like to acknowledge the kind assistance of Dr Barry Nicholls for advice, particularly with regard to the block techniques and Dr Kristine Barnden for proof reading the manuscript.

#### **References**

1. Selander D., Dhuner K.E. and Lundberg E. Peripheral nerve injuries due to injection needles used for regional anaesthesia. *Acta Anaesthesiologica Scandinavica* 1977; 21: 182.
2. Khoo S.T. and Brown T.C.K. Femoral nerve block - the anatomical basis for a single injection technique. *Anaesthesia and Intensive Care* 1983; 11: 40-2.
3. Winnie A.P., Ramamurthy S. and Durrani Z. The inguinal paravascular technic of lumbar plexus anaesthesia. The "3-in-1 Block." *Anesthesia and Analgesia* 1973; 52: 989-96.
4. Dalens B., Tanguy A. and Vanneville G. Sciatic nerve blocks in children: Comparison of the posterior, anterior and lateral approaches in 180 paediatric patients. *Anaesthesia and Analgesia* 1990; 70: 131-7.
5. Labat G. *Regional Anaesthesia, Its Technique and Clinical Application*. Philadelphia. W.J. Saunders. 1924

#### **Further reading:**

1. Macrae W.A. Lower Limb Blocks in Wildsmith J.A.W. and Armitage E.N. (eds)
  2. Bridenbaugh P.O. and Wedel D.J. The lower extremity - somatic blockade. In Cousins M.J. and Bridenbaugh P.O. (eds) *Neural Blockade in Clinical Anaesthesia and Management of Pain* 3rd ed. pp 373 - 94 Lippincott-Raven 1998.
  3. Covino B.G. and Wildsmith J.A.W. Clinical pharmacology of local anaesthetic agents. In Cousins M.J. and Bridenbaugh P.O. (eds) *Neural Blockade in Clinical Anaesthesia and Management of Pain* 3rd ed. pp 97 - 128 Lippincott-
-