

SUB-TENON'S BLOCK

Professor Chandra M Kumar, Academic Department of Anaesthesia,
The James Cook University Hospital, Middlesbrough, UK
Email: Chandra.kumar@stees.nhs.uk

Patient comfort, safety and low complication rates are the essentials of any local anaesthetic technique. The anaesthetic requirements for ophthalmic surgery are dictated by the nature of the proposed surgery, the surgeon's preference and the patient's wishes. Cataract surgery is the commonest ophthalmic surgical procedure and local anaesthesia is the norm. Although akinesia (i.e. the extra-ocular muscles are paralysed) is not essential for modern cataract surgery some ophthalmic surgeons may prefer to operate on immobile eyes. The method of local anaesthesia for cataract surgery varies worldwide and both non-akinetic and akinetic methods are widely used¹⁻³. Non-akinetic methods include topical, subconjunctival, deep fornix anaesthesia and lidocaine gel⁴. Akinetic blocks using needle techniques such as intraconal, extraconal or combined intraconal and extraconal blocks are common, although rare but serious complications have occurred following needle blocks⁴. This has led to the introduction of the newer sub-Tenon's block as a safer alternative⁵.

In sub-Tenon's block, local anaesthetic agent is injected under the Tenon's capsule⁵. This block is also known as parabolbar block⁶, pinpoint anaesthesia⁷ and medial episcleral block⁸. A thorough knowledge of the anatomy of the orbit is a pre-requisite before embarking on a sub-Tenon's block.

Anatomy

The orbit is an irregular four-sided pyramid with its apex pointing posteromedially and its base facing anteriorly. The annulus of Zinn, a fibrous ring arising from the superior orbital fissure, forms the apex. The base is formed by the surface of the cornea, the conjunctiva and the lids. Globe movements are controlled by the rectus muscles (inferior, lateral, medial and superior) and the oblique muscles (superior and inferior). The rectus muscles arise from the annulus of Zinn near the apex of the orbit and insert anterior to the equator of the globe thus forming an incomplete cone. Within the annulus and the muscle cone lie the optic nerve (IInd cranial nerve), the oculomotor nerve (III, containing both superior and inferior branches), the abducent nerve (VI), the nasociliary nerve (a branch of Vth nerve), the ciliary ganglion and blood vessels.

- The *superior branch of the oculomotor nerve* supplies the superior rectus and the levator palpebrae muscles.
- The *inferior branch of oculomotor nerve* supplies the medial rectus, the inferior rectus, and the inferior oblique muscles.

- The *abducens nerve* supplies the lateral rectus.
- The *trochlear nerve (IVth nerve)* runs outside and above the annulus, and supplies the superior oblique muscle (retained activity of this muscle is frequently observed as anaesthetic agents often fail to block this nerve).
- Sensation of the cornea, perilimbal conjunctiva and superonasal quadrant of the peripheral conjunctiva is mediated through the *nasociliary nerve*. The remainder of the peripheral conjunctival sensation is supplied through the *lacrimal, frontal, and infraorbital nerves* coursing outside the muscle cone, hence intra-operative pain may be experienced if these nerves are not blocked.

Tenon's capsule is a thin membrane that envelops the globe and separates it from the orbital fat⁹. The inner surface is smooth and shiny and is separated from the outer surface of the sclera by a potential space called **sub-Tenon's space**. Crossing the space and attaching the fascial sheath to the sclera are numerous delicate bands of connective tissue (Figure 1).

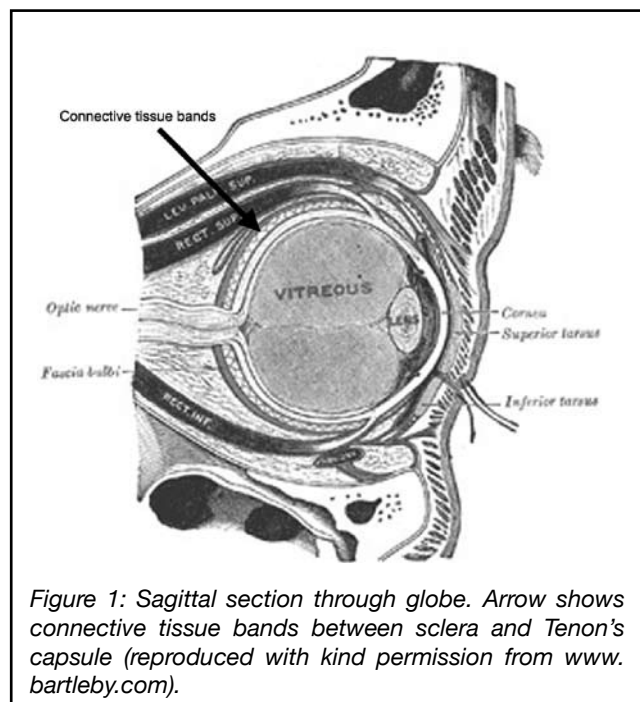


Figure 1: Sagittal section through globe. Arrow shows connective tissue bands between sclera and Tenon's capsule (reproduced with kind permission from www.bartleby.com).

Anteriorly the fascial sheath is firmly attached to the sclera, about 5 mm lateral to the corneoscleral junction. Posteriorly, the sheath fuses with the meninges around the optic nerve and with the sclera around the exit of the optic nerve. Injection of local anaesthetic agent under the Tenon's capsule, blocks sensation from the eye by action on the short ciliary nerves as they pass

through the Tenon's capsule to the globe. Akinesia is obtained by direct blockade of anterior motor nerve fibres as they enter the extraocular muscles. Vision may be affected by direct action on the optic nerve as the anaesthetic solution diffuses along its anterior portion.

Assessment and preparation

Preoperative preparation and assessment vary worldwide. In the UK, the Joint Colleges Working Party Report¹⁰ recommended that patients are not fasted, but fasting policies vary considerably. Complication rates as a result of aspiration under sub-Tenon's block are unknown. Published guidelines and reports^{10,11} suggest that routine investigations for patients undergoing cataract surgery do not alter the outcome of surgery.

Preoperative assessment should always include a specific enquiry about bleeding disorders and related drugs. There is an increased risk of subconjunctival haemorrhage during sub-Tenon's block in patients receiving anticoagulants and this requires that a clotting profile is available (and recorded) prior to injection^{12,13}. However, patients receiving anticoagulants are advised to continue their medication¹², and clotting results should preferably be within the recommended therapeutic range: INR <3.5 is generally accepted in clinical practice. Currently there is no recommendation for patients receiving antiplatelet agents and an increased incidence of subconjunctival haemorrhage is reported¹³.

Pre-block

Anaesthetic procedure is explained to the patients. All monitoring and anaesthetic equipment in the operating environments should be fully functional¹⁰. Blood pressure, oxygen saturation and ECG leads are connected and baseline recordings are obtained¹⁰. A patent intravenous cannula is useful should the need arise.

Technique

Technique involves obtaining surface anaesthesia, instillation of antiseptic, surgical access to the sub-Tenon's space, insertion of a blunt cannula and the subsequent administration of local anaesthetic agent into the sub-Tenon's space¹⁴.

Surface anaesthesia

Effective surface anaesthesia is the key to the success of a sub-Tenon's block. Surface anaesthesia can be achieved either by instilling topical agents such as amethocaine, proxymetacaine or benoxinate on the conjunctiva and cornea, or by the application of a cotton bud soaked with topical agent in the area of dissection¹⁴.

Antiseptic eye drops

There is a UK recommendation that 5% povidone-iodine eye drops should be instilled before embarking on the block⁵⁵. Importantly, 10% povidone-iodine has been shown to be toxic to the cornea¹⁵ and is not

recommended for instillation into the eye.

Surgical access

Sub-Tenon's space can be accessed from all 4 quadrants¹⁴ but the inferonasal quadrant is the most commonly accessed because placement of the cannula in this quadrant allows good fluid distribution superiorly, while avoiding the area of access for surgery and damage to the vortex veins. The patient is asked to look upwards and outwards (Figure 2). Under sterile conditions, the conjunctiva and Tenon's capsule are gripped with non-toothed forceps 5mm to 10mm away from the limbus (Figure 3). A small incision is made through these layers with scissors to expose the white area and the sub-Tenon's cannula is inserted following the globe.

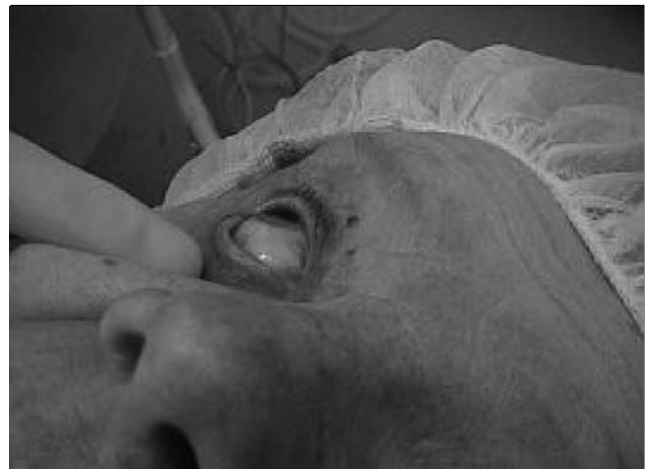

Figure 2: Gaze of the globe during dissection (upward & outward position).

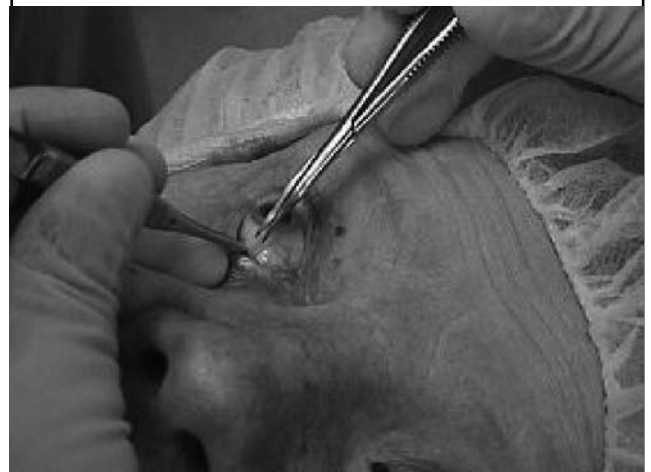

Figure 3: Dissection of sub-Tenon's space using scissors and forceps while the eye is in upward and outward position.

Sub-Tenon's cannulae

Different sub-Tenon's cannulae are available and they are made of either metal or plastic. A typical, commonly used commercial cannulae (Figure 4) is made of metal, is 19G, 2.54cm long and curved with a blunt end¹⁴. There are other commercial and

non-commercial cannulae, which vary in lengths and gauges, and the choice of cannula depends on availability and the preference of the clinician.

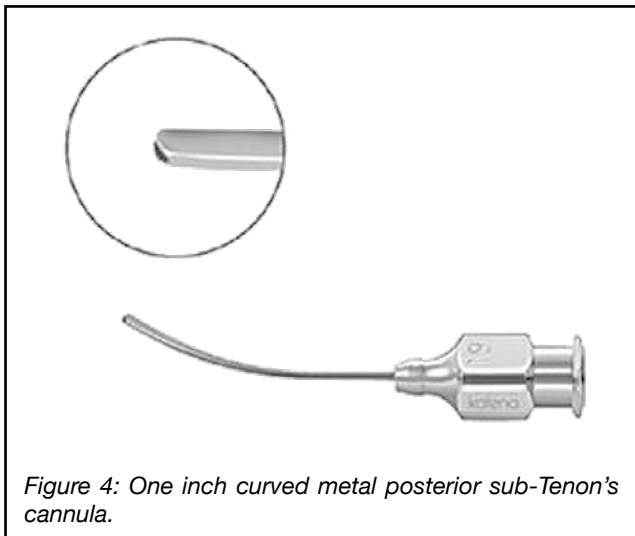


Figure 4: One inch curved metal posterior sub-Tenon's cannula.

Local anaesthetic agent and volume

All the modern, high-potency local anaesthetic agents are suitable for ophthalmic blocks and numerous studies have shown little difference in the quality of anaesthesia, analgesia and akinesia¹⁴, however 2% lidocaine with or without epinephrine and hyaluronidase remains the author's choice. The volume of local anaesthetic agent for sub-Tenon's block varies from 1.5ml to 11ml, but 3 to 5ml is generally used¹⁴.

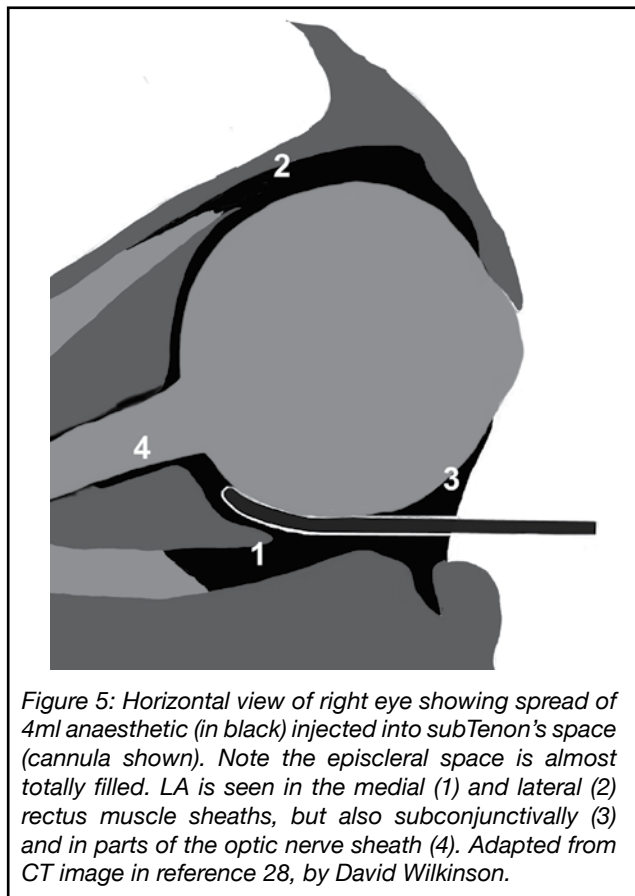


Figure 5: Horizontal view of right eye showing spread of 4ml anaesthetic (in black) injected into sub-Tenon's space (cannula shown). Note the episcleral space is almost totally filled. LA is seen in the medial (1) and lateral (2) rectus muscle sheaths, but also subconjunctivally (3) and in parts of the optic nerve sheath (4). Adapted from CT image in reference 28, by David Wilkinson.

Intra-operative care and monitoring

The patient must be comfortable with soft pads under pressure areas. All patients undergoing major eye surgery under local anaesthesia should be monitored with pulse oximetry, ECG and non-invasive blood pressure measurement. Once the patient is under the drapes, verbal and tactile contact must be maintained throughout the procedure¹⁰. Delivery of oxygen under the drapes produces an oxygen-enriched breathing atmosphere to prevent hypoxia and should be at a flow rate adequate to prevent re-breathing of CO₂ under the drapes.

Uses of sub-Tenon's block

Sub-Tenon's block is a versatile and effective technique^{14,16}. Its use has been advocated primarily for cataract surgery but is also effective for vitreoretinal surgery, panretinal photocoagulation, trabeculectomy, strabismus surgery, optic nerve sheath fenestration and the delivery of drugs¹⁶. This technique is also increasingly favoured in patients who are on anticoagulants, aspirin and non-steroidal anti-inflammatory drugs (NSAIDs)¹⁶.

Effectiveness of sub-Tenon's block

There are conflicting reports on the relative effectiveness of the different techniques for achieving an akinetic block. The evidence indicates that peribulbar and retrobulbar anaesthesia produce equally good akinesia and equivalent pain control during cataract surgery¹¹. There is insufficient evidence in the literature to make a definite statement concerning the relative effectiveness of sub-Tenon's block in producing akinesia when compared with peribulbar or retrobulbar block. Individual studies have revealed contradictory conclusions¹¹. Overall there is moderate evidence that sub-Tenon's block produced better pain control than retrobulbar and peribulbar block. Finally, there was weak evidence that sub-Tenon's block produces better pain control than topical anaesthesia.

Limitations of sub-Tenon's block

Subconjunctival haemorrhage and chemosis are common. Residual muscle movement or incomplete akinesia rarely causes intraoperative difficulties and is generally acceptable to surgeons. The block may be difficult to perform in patients who have had previous sub-Tenon's block in the same quadrant, previous retinal detachment or strabismus surgery, eye trauma or orbital infection. Some glaucoma surgeons do not favour sub-Tenon's block although this block has been used successfully for glaucoma surgery¹⁶.

Complications

Complications arising from sub-Tenon's block may be limited to the orbit and its contents or may manifest systemically^{14,16,17,18}. Some complications arise immediately while others are delayed. While some are minor, others are life and sight threatening. Complications may result from technique of block administration, local anaesthetic agent and adjuvant

drugs (if used). Other medical adverse events unrelated to the block have been reported.

Minor complications

Topical local anaesthetic agent

All local anaesthetic eye drops produce stinging on application, but tetracaine appears to produce more stings¹⁸. Some authorities are concerned that a significant increase in corneal thickness and opacification can result if local anaesthetics enter the anterior chamber of the eye.

Pain during injection

Minor to moderate pain during injection is reported in 46% of patients. The severity of pain is usually of VAS (visual analogue score) <3 but some patients complain of more pain and this is difficult to predict.

All injectable local anaesthetic agents produce a mild stinging or burning sensation on injection. Introduction of the cannula through the potential space into the posterior sub-Tenon's space may cause a feeling of pressure during injection, due to widening and stretching of the potential space.

Pain cannot be completely abolished but severity can be reduced by gentle insertion of the cannula, slow injection of warm local anaesthetic agent and reassurance.

Chemosis

Chemosis is swelling of conjunctiva and this occurs due to anterior spread of the local anaesthetic agent after injection. Mild to severe chemosis occurs after sub-Tenon's block and the incidence varies between 25 to 100%, depending on the length of the sub-Tenon's cannulae used.

Chemosis is unavoidable, but is more likely to occur if dissection of Tenon's capsule is not adequate or a large volume of local anaesthetic is injected. This is usually limited to the site of injection but may spread to other quadrants of the globe.

Presence of chemosis does not usually interfere with cataract surgery but some glaucoma surgeons may not be satisfied. Simple measures such as gentle pressure on the globe limits its spread and may reduce the swelling.

Subconjunctival haemorrhage

A red eye is a common occurrence following sub-Tenon's block. Redness may be due to handling of the conjunctiva causing hyperaemia or it may be real subconjunctival haemorrhage.

Subconjunctival haemorrhage is evitable as small blood vessels are severed during blunt dissection. The incidence of redness varies from 20-100% depending on the length of cannula used¹⁹. The assessment of conjunctival haemorrhage is subjective leading to under- or over-scoring. An objective method using comparison of photographs has been advocated²⁰. The haemorrhage may be limited to the area of

dissection or spread to other quadrants. The incidence of conjunctival haemorrhage is higher in patients receiving anticoagulant, aspirin and clopidogrel¹³. Subconjunctival haemorrhage is not believed to compromise the outcome of glaucoma surgery.

Redness or subconjunctival haemorrhage can be minimised by careful dissection which minimises damage to fine vessels. Epinephrine containing local anaesthetic or application of vasoconstrictor using a soaked cotton bud may reduce the incidence of subconjunctival haemorrhage, but this remains unproven. Ophthalmologists can reduce the incidence of subconjunctival haemorrhage by applying diathermy using an operating microscope^{6,21}, but no such benefit was obtained when anaesthesia personnel²² used disposable diathermy. Application of gentle pressure on the globe may limit the spread of haemorrhage. Patients should be informed that the eye might look red in the immediate postoperative period.

Akinesia and eyelid movements

Rectus muscle and eyelid movements are reduced following sub-Tenon's block but this is variable and unpredictable^{14, 16}.

Akinesia is volume dependent and if 4-5ml of local anaesthetic is injected, a large proportion of patients develop akinesia. Superior oblique muscle and lid movements may remain active in a significant number of patients.

Akinesia is not essential for modern phaco-emulsification surgery, however residual rectus muscle movements may cause inadequate operating conditions for certain procedures.

Major complications

Case reports of sight- and life-threatening complications have been described^{14,16,17,18}. Reports include orbital and retrobulbar haemorrhage due to trauma to blood vessels, rectus muscle paresis by direct trauma from the blunt cannula (ptosis and diplopia), orbital swelling resulting from inflammation, allergy and excessive growth of orbital tissue. Serious life-threatening complications such as central nervous system spread of local anaesthetic causing death have occurred. Sight-threatening complications such as globe perforation, retinal and choroidal vascular occlusion and optic nerve damage (dilated pupils, loss of accommodation, and optic neuropathy) are all reported. Other complications include conjunctival inclusion cyst, intractable glaucoma and cutaneous hypopigmentation.

Many of these complications may be related to inadequate technique or deep insertion of long posterior sub-Tenon's cannula, which enters the posterior part of the sub-Tenon's space^{18, 20}. Careful dissection and slow introduction of a posterior cannula without force is advised. If any resistance is met during insertion of a cannula, it should be

withdrawn, repositioned and reintroduced. The use of smaller and flexible cannulae may offer benefits but the incidence of chemosis and conjunctival haemorrhage increases²³.

Intravascular injection

Local anaesthetic toxicity may result from absorption, intravascular injection, allergic reaction. This may be difficult to differentiate from a vasovagal attack. These complications have been reported after peri- and retrobulbar block but fortunately no such complication has occurred following sub-Tenon's block, presumably because the cannula is blunt. Utilization of a minimum effective dose, volume and concentration together with aspiration before injection and slow injection in fractional amounts, while maintaining verbal contact with the patient (for report of possible systemic symptoms) is considered safe practice.

Other complications

Epinephrine

Admixture with epinephrine is commonly used to prolong the block and reduce absorption of local anaesthetic agent. A concentration (1:200,000) has no systemic effects¹⁸. No adverse effects have been reported during sub-Tenon's block. Epinephrine containing solution should be avoided in patients with severe cardiovascular disease.

Hyaluronidase

Hyaluronidase is used to improve onset, effectiveness and quality of sub-Tenon's block but good anaesthesia and akinesia are possible without it²⁴. The amount of hyaluronidase used during ophthalmic regional anaesthesia varies from 1 to 150 IU/ml. The British National Formulary recommends limiting the concentration to 15 IU/ml²⁵. Orbital pseudotumour and orbital swelling after high dose hyaluronidase have been reported¹⁸. Rarely allergic reactions to hyaluronidase have been described during sub-Tenon's block¹⁸. There is no evidence of muscle dysfunction if hyaluronidase is omitted.

Complications related to sedation

Sedation is appropriate in selected patients, in whom explanation and reassurance have proved inadequate. Routine use of sedation for orbital block is discouraged because of the increased risk of intra-operative events^{10, 26}. When sedation is administered, a means of providing supplementation oxygen, equipment and personnel to manage any life-threatening events must be immediately accessible¹⁰.

Other adverse medical events

A large prospective audit involving 6000 patients conducted in Auckland, New Zealand²⁷ showed no serious complication related to sub-Tenon's block, but some patients suffered cardiovascular complications, unrelated to the block.

Conclusion

Sub-Tenon's block is a simple, effective and

relatively safe technique, but both minor and major complications including life- and sight-threatening complications have occurred. The exact incidence of these complications is not known. At present there is no absolutely safe technique for orbital block.

References

1. Leaming DV. Practice styles and preferences of ASCRS members--2003 survey. *J Cataract Refract Surg* 2004; 30: 892-900.
2. Eke T, Thompson JR. The National Survey of Local Anaesthesia for Ocular Surgery. I. Survey methodology and current practice. *Eye* 1999; 13: 189-95.
3. Eke T, Thompson JR. The National Survey of Local Anaesthesia for Ocular Surgery. II. Safety profiles of local anaesthesia techniques. *Eye* 1999; 13: 196-204.
4. Kumar CM, Dodds C. Ophthalmic regional block. *Ann Acad Med Singapore* 2006; 35: 158-67.
5. Stevens JD. A new local anesthesia technique for cataract extraction by one quadrant sub-Tenon's infiltration. *Br J Ophthalmol* 1992; 76: 670-4.
6. Greenbaum S. Parabolbar anesthesia. *Am J Ophthalmol* 1992; 114: 776.
7. Fukasaku H, Marron JA. Sub-Tenon's pinpoint anesthesia. *J Cataract Refract Surg* 1994; 20: 673.
8. Ripart J, Lefrant JY, Vivien B, Charavel P, Fabbro-Peray P, Jaussaud A, Dupeyron G, Eledjam JJ. Ophthalmic regional anesthesia: medial canthus episcleral (sub-tenon) anesthesia is more efficient than peribulbar anesthesia: A double-blind randomized study. *Anesthesiology* 2000; 92: 1278-85.
9. Snell RS, Lemp MA, editors. *Clinical Anatomy of the Eye*. Boston: Blackwell Scientific Publications 1989.
10. Local Anaesthesia for Intraocular Surgery: The Royal College of Anaesthetists and The Royal College of Ophthalmologists 2001.
11. Agency for Healthcare Research and Quality. Evidence Report/Technology Assessment: Number 16: Anaesthesia Management During Cataract Surgery. Available at <http://www.ahrq.gov/clinic/epcsums/anestsum.htm> accessed on 18th November 2004.
12. Konstantatos A. Anticoagulation and cataract surgery: A review of the current literature. *Anaesth Intensive Care* 2001; 29: 11-8.
13. Kumar N, Jivan S, Thomas P, McLure H. Sub-Tenon's anesthesia with aspirin, warfarin, and clopidogrel. *J Cataract Refract Surgery* 2006; 32: 1022-25.
14. Kumar CM, Williamson S, Manickam B. A review of sub-Tenon's block: current practice and recent development. *Eur J Anaesthesiol* 2005; 22: 567-77.
15. Ta CN. Minimizing the risk of endophthalmitis following intravitreal injections. *Retina* 2004; 24: 699-705.
16. Kumar CM and Dodds TC. Unpublished data from ophthalmic clinic.
17. Kumar CM, Dowd TC. Complications of ophthalmic regional blocks: their treatment and prevention. *Ophthalmologica* 2006; 220: 3-82.
18. Kumar CM. Orbital regional anesthesia: complications and their prevention (Review). *Indian J Ophthalmol* 2006; 54: 77-84.
19. Kumar CM, Dodds C, McLure H, Chabria R. A

- comparison of three sub-Tenon's cannulae. *Eye* 2004; 18: 873-6. Erratum in: *Eye* 2004; 18: 1279.
20. Kumar CM, Dowd TC, Adams WE, Puckering S. Methodology of evaluating conjunctival appearance following sub-Tenon's block for phacoemulsification cataract surgery. *Eye* 2006; 20: 1110-1.
21. Gauba V, Saleh GM, Watson K, Chung A. Sub-Tenon anaesthesia: reduction in subconjunctival haemorrhage with controlled bipolar conjunctival cautery. *Eye* 2006; [Epub ahead of print].
22. Kumar CM, Williamson S. Diathermy does not reduce subconjunctival haemorrhage during sub-Tenon's block. *Br J Anaesth* 2005; 95: 562.
23. Kumar CM, Dodds C. An anaesthetist evaluation of Greenbaum sub-Tenon's block. *Br J Anaesth* 2001; 87: 631-3.
24. Alwitary A, Chaudhary S, Gopee K, Butler TK, Holden R. Effect of hyaluronidase on ocular motility in sub-Tenon's anaesthesia: randomized controlled trial. *J Cataract Refract Surgery* 2002; 28: 1420-3.
25. British National Formulary. A joint publication of the British Medical Association and the Royal Pharmaceutical Society of Great Britain: London 2002.
26. Katz J, Feldman MA, Bass EB, Lubomski LH, Tielsch JM, Petty BG et al. Study of Medical Testing for Cataract Surgery Study Team. Adverse intraoperative medical events and their association with anesthesia management strategies in cataract surgery. *Ophthalmology* 2001; 108: 1721-6.
27. Guise PA. Sub-Tenon anaesthesia: a prospective study of 6,000 blocks. *Anesthesiology* 2003; 98: 964-8.
28. Ripart J, Metje L, Prat-Pradal D, Lopez F-M, Eledjam J-J. Medial canthus single-injection episcleral (subTenon) anaesthesia: computed tomography imaging. *Anaesth Analg* 1998; 87: 42-5.
-